

Asian Resonance

Branching Pattern of Facial Nerve as Seen in Parotidectomy

Padam Singh Jamwal

Associate Professor,
Deptt. of E.N.T & Head and Neck Surgery
Government Medical College & Associated Hospitals,
(S.M.G.S. Hospital), Jammu

Mohit Goel

P.G. 3rd Year,
Deptt. of E.N.T & Head and Neck Surgery
Government Medical College & Associated Hospitals,
(S.M.G.S. Hospital), Jammu

Manish Sharma

Registrar,
Deptt. of E.N.T & Head and Neck Surgery
Government Medical College & Associated Hospitals,
(S.M.G.S. Hospital), Jammu

Abstract

This study examines the types of branching patterns of facial nerve during parotid gland surgery as classified by Davis (1956), incidence of each type of branching in parotid surgeries and length of main trunk of facial nerve and its distance from tympanomastoid suture. The study was conducted on a total of 20 patients who were admitted in the department of ENT, GMC, Jammu. The most common type of branching pattern in our study was type I (45%), followed by type III(30%), type II(10%), type IV(10%), type VI(5%) while none had the type V pattern. 13 patients out of 20 had 16-20mm length of the main trunk of facial nerve. 6 had the length of 11-15mm, one case had length greater than 20mm while none had the main trunk less than 10mm. 55% cases had a distance of 2.5 – 3mm while only 10% had the distance of >3.5mm between the facial nerve and the tympanomastoid suture. It was observed that all the cases had the Marginal mandibular nerve running below the inferior border of mandible and in 60% of the cases it was 1-1.5cm below while in 30% it was 1.6-2cm running below the inferior border of mandible. In view of the above findings, in the parotid surgery if the branching variations, variations in length of main trunk, distance of the nerve from tympanomastoid suture are kept in mind, the surgeon will be safe from unpleasant surprises.

Keywords: Facial Nerve, Parotidectomy, Branching Pattern of Facial Nerve

Introduction

Superficial or total parotidectomy with preservation of the facial nerve has been commonly used in the surgical treatment of parotid gland tumors. The challenge to the surgeon during parotid surgery is to carefully dissect and preserve the facial nerve. Therefore the knowledge of facial nerve anatomy and its variations is vitally important. Many landmarks are used for its identification like tragal pointer, tympanomastoid suture, posterior belly of digastric, mastoid process, peripheral branches (Hoille et al 2008) but until now there is no conclusive evidence for the best single landmark.. Davis(1956) categorized the branching patterns of facial nerve within parotid gland into six types. Our study has been conducted to determine the branching patterns of facial nerve as seen during parotidectomy with special focus to the relation of main trunk to the surrounding fixed bony landmarks.

Aims and Objectives

The prospective study comprising of 20 cases of parotidectomy was carried out in the department of ENT and head and neck surgery, GMC Jammu from Nov. 2011 to Oct. 2012. The Following were the aims and objectives:-

1. To classify the branching pattern of facial nerve as per Davis (1956) classification during parotid gland surgery.
2. To determine the percentage of various types of branching patterns of facial nerve during parotid gland surgery.
3. To determine the length of the main trunk of facial nerve.

Material and Methods

The study was conducted on a total of 20 patients who were admitted in the department of ENT, GMC, Jammu for parotidectomy for various etiologies from Nov. 2011 to Oct. 2012.

Patients who had pre-operative facial nerve palsy / paresis, fixation of tumor to overlying skin, lymph node involvement and recurrent lesion were excluded from the study.

After detail history and ENT examination, FNAC of the gland and CT was done. Pre-operative anesthetic check-up was done and parotidectomy was carried out as give below.

Asian Resonance

The patient was placed with 15 head up to reduce venous congestion. A sand bag was placed under the ipsilateral shoulder and head turned away from the surgeon. The skin of one side of face and neck was prepared.

Modified blairs incision was given beginning near the upper part of auricle running downwards into the tragal notch, continuing to the lobe of the ear, then curving backwards at almost a right angle to the tip of the mastoid process and finally curving gently downwards towards the hyoid bone in a skin crease.

The skin flaps were elevated forward to the edge of the mascetue muscle.The gland was separated from the cartilagenous external auditory caral until whole of the cartilageous meatus was free.

The gland was held forwards with a malleable retractor and the nerve was located by opening up an artery forceps parallel to the nerve using the landmarks for facial nerve identification.

Repeating these four steps, insert, spread, lift and cut, tunneling along each branch consecutively starting at the top and working down and by cutting the piece of parotid that lies between the two branches, peel the parotid from above downwards.

As the gland was lifted, the duct was located at its mid portion which was then divided and ligated.

If the deep lobe was involved and facial nerve uninvolved, it was dissected out leaving the facial nerve intact.

Two primary divisions of facial nerve were identified and small anastigmatic branches between the terminal branches were carefully dissected.

The skin was closed in two layers. The branching pattern was classified into six types based on the description by Davis (1956) i.e.

Type I	No anastomosis between branches of Facial Nerve
Type II	Presence of an anastomotic connection between branches of Temporofacial division.
Type III	A single anastomosis between temprofacial and cervicofacial division.
Type IV	A combination of Type II & III
Type V	Two anastomotic ramii passed from cervicofacial division to interwine with branches of temprofacial division.
Type VI	Plexi form arrangement, the mandibular branch sends twing to join any members of temprofacial division.

The percentage of each type was calculated. Length of the main trunk was determined and recorded.

The relationship of marginal mandibulars nerve to inferior border of mandible was also determined and recorded.

The relationship of facial nerve to tympanomastoid suture was also determined using sterile measure (wire / thread) which was then measured on caliper and recorded.

Observations

Out of 20 patients, 10 were males and 10 were females. 45% of the patients were in the age group of 31 to 40 years and maximum(85%) had pleomorphic adeaoma as the cause of swelling in the parotid.

Table 1
Showing branching pattern of facial nerve (n – 20).

Type of branching pattern	Number	Percentage
Type I	9	45%
Type II	2	10%
Type III	6	30%
Type IV	2	10%
Type V	0	0%
Type VI	1	5%

The most common type of branching pattern in our study was type I (45%) while none had the type V pattern.

13 patients out of 20 had 16-20mm length of the main trunk of facial nerve. 6 had the length of 11-15 mm, one case had length greater than 20mm while none had the main trunk less than 10mm.

Table 2
Showing the distance of Facial nerve from Tympanomastoid suture.

Distance from T/M suture	<2.5mm	2.5 - 3mm	3-3.5mm	>3.5mm
Number (n-20)	4	11	3	2
Percentage	20%	55%	15%	10%

Maximum i.e. 55% cases had a distance of 2.5 – 3mm while only 10% had the distance of >3.5mm between the facial nerve and the tympanomastoid suture.

Table 3
Showing the distance of Marginal mandibular nerve from inferior border of mandible

Distance	Number	Percentage
<1cm below the inferior border of mandible	2	10%
1-1.5cmbelow the inferior border of mandible	12	60%
1.6-.2cm below the inferior border of mandible	6	30%

It was observed that all the cases had the Marginal mandibular nerve running below the inferior border of mandible and in 60% of the cases it was 1- 1.5cm below while in 30% it was 1.6-2cm running below the inferior border of mandible

Discussion

The present study deals with the characters of ramification of peripheral branches of facial nerve during its cause in parotid gland. Various authors have conducted a study on the branching pattern of facial nerve in the Parotid from time to time based on classification given by Davis (1956) like Myint (1992), Ekinci (1994), Kim Suh (2002) and Ahmed (2004).

Out study compared the results with those given by these authors:-

Asian Resonance

TABLE 4
Percentage of various type of branching patterns of facial nerve as given by different authors based on Davis classification:-

Author	Type I	II	III	IV	V	VI
Davis (1956) N – 356	13%	20%	28%	24%	9%	6%
Myint (1992) N – 79	11.4%	16%	34%	19%	7.6%	12.7%
Ekinci (1994) N-27	52%	7%	7%	30%	4%	-
Kim Suh (2002) N – 23	57%	17%	17%	9%	-	4%
Ahmed (2004) N – 57	26.3%	-	36.7%	26.3%	-	-
Present study	45%	10%	30%	10%	-	5%

The most common branching pattern in the present study was type I (45%). Similar findings were observed by Ekinci (1994) and Kim Suh (2004). However Type III was found to be the common pattern in the studies conducted by Davis (1956) 28% , Myint (1992) 34% and Ahmed (2004) 36.7%.

The least common branching pattern in all the studies was either type V or type VI and Type V was not found even in a single patient in the studies conducted by Kim Suh (2002), Ahmed (2004) and the present study. Type VI pattern was not seen at all in the studies by Ekinci (1994) and Ahmed (2004).

The average length of the main trunk of facial nerve was 16.45mm which is in accordance with Kwale and Park (2004) and Salame (2002) who reported the length in their studies to be 13.0 + 2.8mm and 16.44 + 3.2mm respectively. Ekinci (1994) however reported the average length to be just 6-12mm.

Most cases (55%) had a distance of 2.5 -3 between the nerve and the tympanomastoid suture which is in accordance with the results of Alexander (2001) who found the distance to be 2.7mm.

In all the cases in the present study the marginal mandibular nerve was found running below the inferior border of mandible with the average distance of 14.2mm. Same fact was reported by Nason in 2007 but in his study the average distance was found to be >10mm.

Conclusion

The following conclusions were drawn Most common pattern of facial nerve branching in the present study was type I followed by the type III.

Least common patterns were type VI and type V.

The average length of main trunk of facial nerve was 16.45mm and most of the patients had the length between 16-20mm.

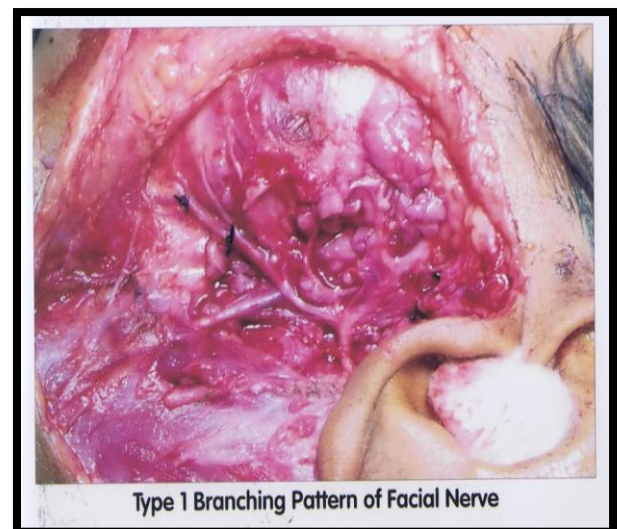
Distance of main trunk from Tympanomastoid suture in 55% cases was 2.5 to 3mm.

Marginal mandibular nerve was always found running below the inferior border of mandible with the average distance between the two to be 14.2mm.

In view of the above findings, in the parotid surgery if the branching variations, variations in length of main trunk, distance of the nerve from tympanomastoid suture are kept in mind, the surgeon will be safe from unpleasant surprises.

References

- (1) Davis R A, Anson B J, Budlinger J M et al. Surgical anatomy of the facial nerve and parotid gland as based upon a study of 350 cervicofacial halves. *Surg Gynecol obstet* 1956; 102: 385-413
- (2) Myint K, Azian AI, Khairul FA. The clinical significance of the branching pattern of the facial nerve in Malaysian subjects. *Med J Malaysia* 1992;47:114-21.
- (3) Ekinci N. A study on the branching pattern of the facial nerve of children (in Japanese). *Kaibogaker Zasshi* 1999;74:447-50.
- (4) Kim Y S, Suh Y J, Kim W. Branching pattern of the facial nerve in the parotid gland. *J. Koreansurg soc* 2002;62:453-455.
- (5) Kwale H H, Park H D, Youn K H et al. Branching patterns of the facial nerve and its communications with the auriculotemporal nerve. *Surg Radiol Anat* 2004;26:494-500.
- (6) Saylam C, Ulcelrer H, Orhan M et al. Localization of the marginal mandibular branch of the facial nerve. *J Craniofacial Surg* ,2007;18:137-42.
- (7) Alexander J, Peter P G, Herman L, et al. Landmark for Parotid gland surgery. *J of Laryngol and otol* 2001;115:122-125.
- (8) Nason R W, Binahmed A, Torchia M G and Thliversis J. Clinical observations of anatomy and functions of the marginal mandibular nerve. *Int J of Oral and Maxillofacial surgery* 2007;36:712-715.



Type I Branching Pattern of Facial Nerve

Asian Resonance

